



**PATIENT**

Kirby Johnson

**SPECIES**

Canine

**BREED**

Bouvier

**SEX**

Male Intact

**AGE**

11 years

**WEIGHT**

56.7lbs

**INTERPRETED BY**

Maggie Machen  
 Lamy, DVM, DACVIM  
 (Cardiology)

**IMAGING PERFORMED BY**

Sara Hansen

**HOSPITAL NAME**

West Hills Animal  
 Hospital

**REFERRING VET**

Dr. Remcho

**INVOICE**

29062

**DATE**

2/16/23

**PRESENTING CLINICAL SIGNS**

History: ProBNP 4138, ALT 130.

-Current medications: Finasteride 5mg PO q24h.

-Radiographs: There is a very mild caudodorsal bronchointerstitial pulmonary pattern. The remainder of the thorax is normal.

**ECHOCARDIOGRAM FINDINGS**

2D, m-mode, color flow and doppler imaging is available. Mild diffuse thickening of mitral valve leaflets with no prolapse into the left atrial lumen. No mitral regurgitation with no left atrial dilation. Normal LV diameter with adequate myocardial function for this signalment. The tricuspid valve appears normal with trace tricuspid regurgitation. Normal velocity. Normal right atrial and ventricular diameter and morphology indicating no overt evidence of pulmonary arterial hypertension. The pulmonic and aortic valves are normal in morphology and mobility. Normal pulmonic and aortic outflow velocities with laminar flow. Trace aortic and pulmonic insufficiency. No pericardial or pleural effusion noted. No obvious cardiac masses.

**CARDIAC CHART**

CANINE CARDIAC PARAMETERS	MR VMAX (m/s)	TR VMAX (m/s)	LA/AO (Boon method)	LA/AO (Heart Base; Swe)	FS (%)	EF (%)	EPSS (cm)
NORMAL PARAMETER	4.5-5.5	<2.7	1.3	<1.6	28-40	40-100	<0.6
PATIENT	NA	2.4	1.1	1.1	27	50	1.1
CANINE CARDIAC PARAMETERS	HR (BPM)	AV VMAX (m/s)	PV MAX (m/s)	BODY WEIGHT (kg)	LA 2D short axis Base view (cm)	LVIDd Avg; 2D and m-mode short axis (cm)	LVIDs Avg; 2D and m-mode short axis (cm)
NORMAL PARAMETER	50-100	0.7-1.7	0.7-1.6	BELOW	BELOW	BELOW	BELOW
PATIENT		1.6	0.82	25.7	2.4	4.8	2.6
*Normal chamber parameters expressed as a mean value (SD)				3	1.27 (5.3)	2.46 (2.46)	1.36 (5.5)
<b>BODY WEIGHT DEPENDENT PARAMETERS</b>				5	1.40 (4.5)	2.74 (5.2)	1.60 (4.7)
				10	1.50 (3.8)	3.27 (3.5)	2.06 (3.1)
				15	1.83 (2.0)	3.71 (2.4)	2.43 (2.1)
				20	2.02 (1.9)	4.14 (2.2)	2.80 (2.0)
				25	2.18 (2.4)	4.48 (2.9)	3.10 (2.5)
				30	2.33 (3.3)	4.83 (3.9)	3.39 (3.4)
				35	2.48 (4.3)	5.17 (5.0)	3.69 (4.5)
				40	2.62 (5.2)	5.48 (6.1)	3.96 (5.4)
				50	2.88 (7.1)	6.07 (8.3)	4.46 (7.4)

Adapted from June Boon, Veterinary Echocardiography, 1998  
 Rishniw M and Hollis NE, J Vet Intern Med 2000; 14:429-435  
 Hansson et al, Vet Rad and Ultrasound 2002  
 Bonagura et al. Echocardiography: principles of interpretation, Vet Clin North Am 15:1177, 1995



**PATIENT**

Kirby Johnson

**SPECIES**

Canine

**BREED**

Bouvier

**SEX**

Male Intact

**AGE**

11 years

**WEIGHT**

56.7lbs

**INTERPRETED BY**

Maggie Machen Lamy, DVM, DACVIM (Cardiology)

**IMAGING PERFORMED BY**

Sara Hansen

**HOSPITAL NAME**

West Hills Animal Hospital

**REFERRING VET**

Dr. Remcho

**INVOICE**

29062

**DATE**

2/16/23

**INTERPRETATION OF THE FINDINGS & FURTHER RECOMMENDATIONS**

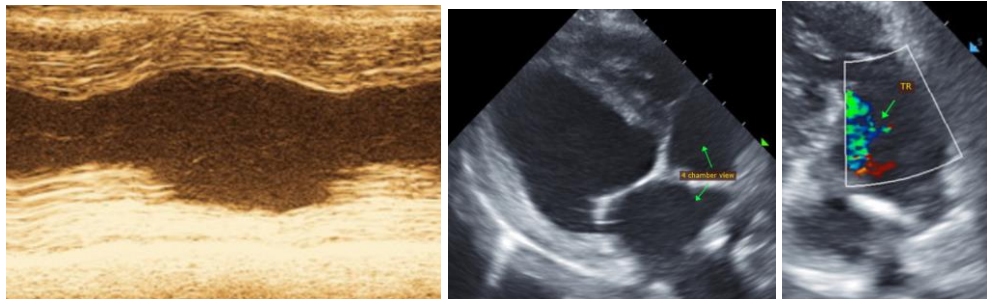
The cardiac structure and function in this patient is overtly normal. No significant valvular regurgitation is noted, and the cardiac dimensions and function are normal. A small aortic insufficiency is noted, and a baseline BP recommended.

No obvious reason for NT-proBNP elevation is seen, most likely making this a false positive result (a known weakness of the test). Other possible causes should be considered, including **hypertension** or renal disease. If no obvious cause is identified, reassessing this patient in 6-12 months is recommended to ensure early disease was not missed.

No cardiac medications are indicated at this time. Monitor for development of a cough, labored breathing, exercise intolerance or collapse episodes. No cardiac contraindication for general anesthesia.

A recheck is recommended in 6-12 months to ensure no progressive issues are identified, sooner should a murmur or any clinical signs of cardiac compromise be noted at home.

**IMAGES**



The information and recommendations provided are based on the images presented by the referring veterinarian. No evaluation can be communicated regarding pathology that was not visible in the image/video clips provided.

Thank you for this referral. This report was generated using transcription software, and minor dictation errors may be present. If the clinical or image interpretation does not parallel your findings or if I can be of any further assistance please contact me.

Maggie Machen Lamy, DVM  
Diplomate of the American College of Veterinary Internal Medicine (Cardiology)  
info@sonopath.com